

# Four Year Experience of Hypospadias Surgery in a Tertiary Care Center with Snodgrass and Two-stage Bracka Repair

Yawar Sajjad, Afsar Ali, Tanveer Anwar

---

## Abstract

**Objectives:** The purpose of our study is to evaluate the outcome of hypospadias reconstruction using two different techniques (Snodgrass and two-stage Bracka Repair) in different types of hypospadias patients. **Study Design:** Case series. **Methods:** Over a period of 4 years from Nov 2009 to Nov 2013 we operated 38 patients of hypospadias in the department of Plastic & Reconstructive surgery and surgical unit II Lahore General Hospital Lahore. The age of patients ranged from 1 to 14 years (mean 7 years). Among these patients 8 patients had previous multiple surgeries (3-6 procedures). Initial repair comprised tubularized incised plate repair (Snodgrass) in 12 patients, two-stage Bracka repair in 26 patients. **Results:** Satisfactory results were obtained in 33 (86%) patients.

Final location of urethra at glans tip achieved in 36 (94%) patients. Urethral fistula developed in 2(5%) patients operated with Bracka's repair and in 1(2.5%) patients with Snodgrass urethroplasty. There was no incidence of proximal stenosis, diverticulum or urethral stricture. Meatal stenosis seen in 2(5%) patients. **Conclusion:** Versatility of Bracka's staged reconstruction enables its use in all types of hypospadias with consistently reproducible results. In selected cases of primary hypospadias when partial circumference urethroplasty is required the tubularized incised plate (TIP) repair is a simple and effective solution. **Key words:** Hypospadias, Snodgrass Urethroplasty, Bracka's technique, Fistula.

---

## INTRODUCTION

Hypospadias is a challenging field of urogenital reconstructive surgery with different techniques being currently used<sup>1</sup>. First recorded hypospadias surgery consisted of penile amputation distal to the existing meatus<sup>2</sup>. The modern age of

hypospadias surgery began in the 1950, with the advent of reliable single staged procedures for simultaneous correction of chordee and repair of hypospadias. First skin graft urethroplasty devised by Nove Joserand using split thickness skin graft to fill a channel in the penis. Brown (1936) Smith (1938) and Schaffer made an anatomical classification of hypospadias according to the localization of ectopic meatus<sup>3</sup>.

1974 Gitle McLanghin popularized artificial erection test, an advance in the diagnosis and treatment of chordee<sup>4</sup>. In 1980 silicon foam dressing was introduced. Local blocks then

Corresponding Author:

Dr. Yawar Sajjad

Assistant Professor

Plastic and Reconstructive Surgery

Lahore General Hospital, Lahore

Tel. +923314409880

E-mail: [dryawar@gmail.com](mailto:dryawar@gmail.com)

---

improved magnification technique and new suture materials (Manley and Epstein 1981) were the milestones in modern hypospadiology<sup>5</sup>. Single stage procedure for all types of hypospadias was described by Humby in 1941 but since its introduction the Snodgrass procedure has been widely adopted which is testament to its successful use<sup>5,6</sup>. Multi stage repair methods were earlier described for hypospadias correction, but recently described two-stage Bracka repair has become a widely accepted staged procedure<sup>7,8</sup>.

Over a period of 4 years from Nov 2009 to Nov 2013, 38 patients operated for different types of hypospadias in the department of plastic surgery Lahore General Hospital Lahore. Among these 22 patients with proximal and secondary hypospadias operated by Bracka's repair and 16 patients with distal and coronal hypospadias repair done by Snodgrass urethroplasty.

Each patient evaluated as regard site of native urethral opening, degree of chordee and operative technique to be used. Patients follow up done for assessment regarding complications such as urethral fistula formation, meatal stenosis and dehiscence.

### **SURGICAL TECHNIQUE**

After assessment of type of hypospadias and status of urethral plate, decision made regarding the selection of procedure.

In Bracka, 1<sup>st</sup> stage, patients were operated under GA with caudal block. Assessment under GA made regarding position and size of meatus, presence of chordee, width of urethral plate. Saline erection test performed by putting needle in the corpora cavernosa. Release of chordee done by making incision from the neomeatus to the abnormal meatus site. Then lateral incision made from the subcoronal site to correct the chordee. Circumferential degloving done only in selected cases in which chordee persisted even after ventral release. In most cases inner preputial skin used as skin graft. Buccal mucosa and post auricular skin was used in selected cases where preputial skin

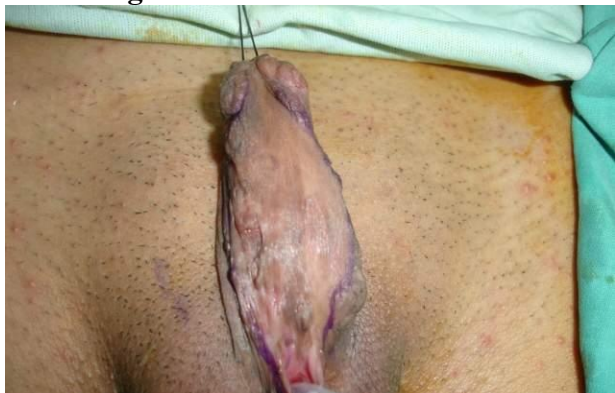was not available due to previous surgery. Tie over foam dressing used for graft stabilization till the 7<sup>th</sup> post operative day. Graft secured with vicryl Rapid 5/0 from distal to proximal.

2<sup>nd</sup> stage done 6 months following the first stage after ensuring the adequate graft take. Under GA with caudal block the adequacy of meatus assessed. Tourniquet of finger glove used and applied with artery forceps. Marking for the tube done so that it can admit feeding tube of 8-10 French depending upon age of patient (Fig.1). Magnification loupes of 2.5 used for repair of hypospadias. Incision made at the periphery of previously applied graft avoiding undermining of graft so that blood supply of graft not compromised (Fig 2). Tubularization was done by applying 6/0 Pds extra luminal sutures (Fig 3). The repair was reinforced by using an intermediate vascularized fascial layer dissected from the dorsal aspect (Fig 4). After completion of repair (Fig 5, 6) tourniquet released hemostasis done and paraffin tulle gauze applied around the penis.

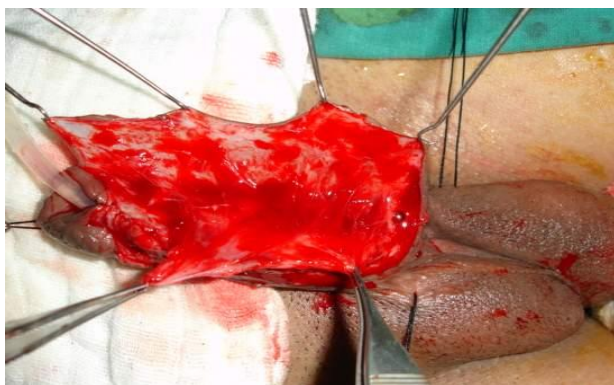
In 12 patients operated with Snod grass the key steps were as;

A circumcising incision made 1-2 mm proximal to the hypospadias meatus and the penis degloving done up to penoscrotal junction. Artificial erection test performed to test the chordee. Mild persistent chordee corrected by dorsal plication. Two parallel longitudinal incision made 6-8 mm apart to define the urethral plate. The edges of urethral plate elevated and retracted laterally with fine forceps. The plate then incised in the midline from the meatus to the tip of the glans. The incision then carried deeply dividing all transverse webs and exposing the corporal bodies. The epithelial strips created by longitudinal incisions. Water proofing done with dorsal subcutaneous tissue.

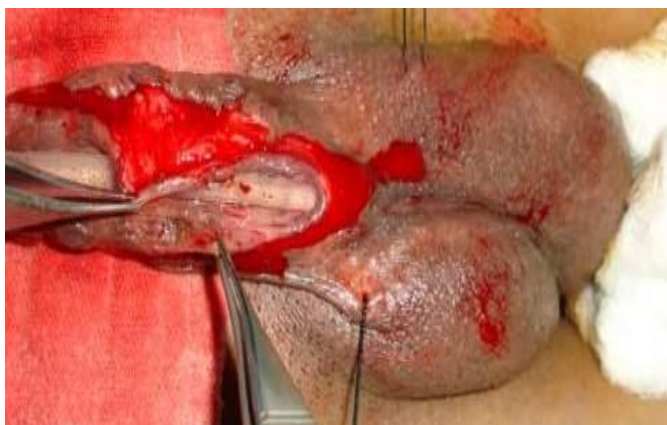**Figure-1**  
Second stage Bracka's Repair graft marking  
for tubing



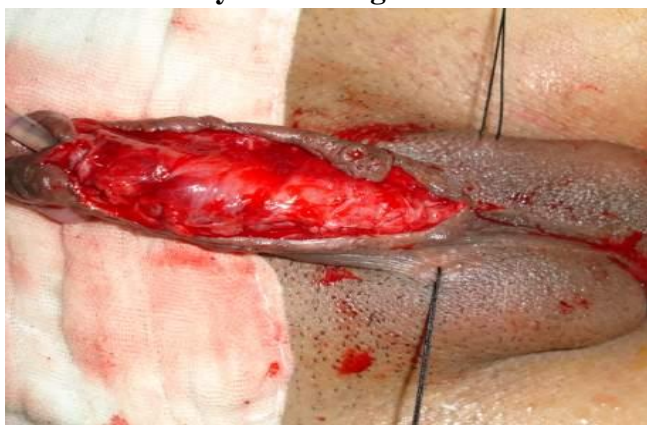**Figure-4**  
Water proofing



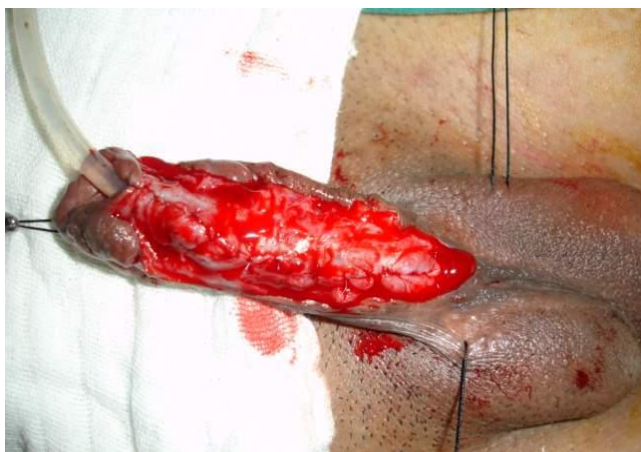**Figure-2**  
Graft incised



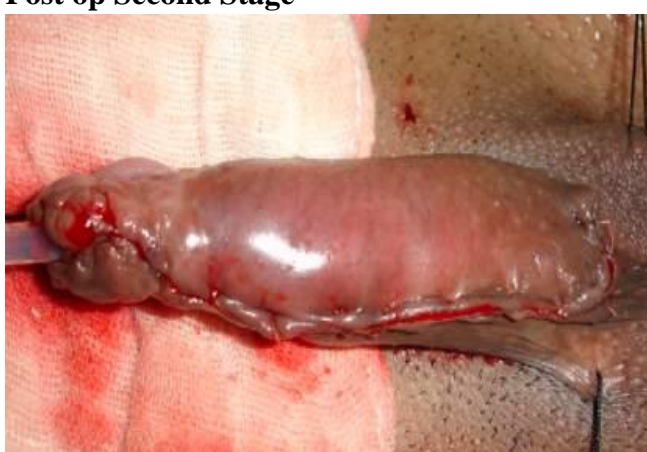**Figure-5**  
Intermediate layer covering neo-urethra



**Figure-3**  
Tubularization done



**Figure-6**  
Post op Second Stage



## RESULTS

During period of 4 years 38 patients with hypospadias underwent treatment using the Brackas' repair and Snodgrass urethroplasty. Patient age ranged from 1-14 years with mean age of 7 year. Initial severity of hypospadias is shown in table 1.

Perineal 2 penoscrotal 4 proximal shaft 6 midshaft 10 distal shaft 6 and coronal 10. 22 patients operated with two staged Bracka technique and 16 patients with Snod grass urethroplasty.

Follow up ranged from 3-24 months. Assessment of all patients done regarding complications such as urethral fistula formation, meatal stenosis and dehiscence. Final location of meatus was glans in 36 patients (95%) and Corona in 2 patients (5%). Urethrocutaneous fistula occurred in 3 patients (7%) for which repair done later on. The urinary stream was straight in 35 (92%) with 3 patients (7%) having a slightly diverted stream. Meatal stenosis reported in 2 patients (5%). Meatal stenosis seen in 1 patients (2%) after Bracka repair and in 1(2%) after Snodgrass urethroplasty. The stenosis was managed in these patients with simple meatotomy.

**Table-1**

**Types of Hypospadias No of patients**

Types of Hypospadias	No of patients
Coronal	10
distal shaft	6
Midshaft	10
proximal shaft	6
Penoscrotal	4
Perineal	2

**Table-2**

**Cosmetic and Functional Outcome**

	Bracka	Snod Grass
Cosmetic appearance satisfactory	20	15
Urinary stream straight	21	15
Meatal stenosis	1	1
Fistula	2	1

Residual chordee seen in 2 patients (5%) after Bracka 1st stage repair and they underwent Redo bracka1. Chordee correction was satisfactory then and they underwent Bracka 2<sup>nd</sup> stage after 6 months. The data were entered and analyzed in Statistical Program SPSS version 22.0. P values less than 0.05 were considered significant.

## DISCUSSION

A number of techniques have been described for repair of Hypospadias. No single method has been sufficient to treat all forms of hypospadias. Success in hypospadias surgery certainly demands to gain experience in more than one procedure. Initially two staged repair was described in early history of hypospadias surgery. Later on replaced mostly by single stage repair with incorporation of urethral plate and addition of dorsal plication for penile straightening. Successful reconstruction depends on proper planning and selection of procedure. In patients with distal shaft hypospadias and mild curvature, single stage repair can be applied. The technique should be tailored to each individual case mainly based on the degree of curvatures and quality of urethral plate. Established procedures for correcting distal hypospadias include Thiersch-Duplay, Mathieu, Meatal Advancement and Glanuloplasty (MAGPI), and TIP Urethroplasty (Snodgrass)<sup>5,6,7,8,9</sup>. Snodgrass described the tubularized incised plate (TIP) for repair of hypospadias in 1994. Since its introduction the Snodgrass procedure has been widely accepted option as single stage procedure. Most of the distal penile cases and coronal cases, in our study were successfully treated in single stage. Straightening of penile shaft achieved by release of fibrous remnants on the ventral aspect and urethra created by tubularization of urethral plate. The longitudinal incision on urethral groove described by Snodgrass is considered an innovation to urethral plate preservation surgery. It allows tension-free tubularization of the narrow urethral plate to form a neourethra of an adequate size. In an experimental study, Bluestein and co-

---

authors confirmed that healing of the midline incision of the urethral plate during urethroplasty occurred by re-epithelialisation with normal tissue ingrowth and without scarring or contracture<sup>10</sup>. These features may explain why few urethral strictures are encountered using this technique. Tubularized incised plate urethroplasty has been accepted as procedure of choice in primary case of distal hypospadias with minimum chordee. Using this technique we had satisfactory results comparable with previously mentioned series. Borer et al and Elevik M et al also suggested TIP is safe if urethral plate is intact and scarless<sup>11</sup>.

Aiver Bracka though presented a two stage technique accepted TIP as procedure of choice for all primary cases with distal hypospadias and some proximal with minimal chordee. If the urethral plate is not available and there is inadequate penile skin, the free graft is the material of choice. In patients with severe chordee and secondary cases, Snodgrass and Lorenzo reported complication rate of 20 %<sup>5,6</sup> while Borer et al reported complication rate of 24% by TIP<sup>11</sup> which again shows the TIP application in primary cases with intact urethral plate.

Despite the potential enhancement of width with the midline relaxing incision, occasionally narrow and inelastic urethral tube requires substantial augmentation. In proximal hypospadias and secondary cases urethral plate transection become inevitable and full circumference urethroplasty is required.

Bracka two-stage repair reconstructing the new urethra with prepuce, buccal mucosa or post auricular graft becomes a reliable procedure; it allows adequate release of ventral chordee tissue and preserves penile length. The Aivar Bracka's two stage repair now a day is the most commonly performed procedure worldwide. It achieves all the goals of hypospadias with short learning curve and with good patient satisfaction rate.

A six month interval between two stages gives graft a chance to mature and become supple. Chordee is corrected in first stage. Bracka in a

series of more than 100 procedures reported a gross fistula rate of 5.7% which mostly occurred during the learning curve and similar results also reported by Hensle et al<sup>8</sup>. We in our series reported a gross fistula rate of 7% in all patients but we operated 8 secondary cases also. So fistula rate on the higher side is due to inclusion of secondary cases in our series, as 2 patients in which fistula formation seen was having previous failed repair at some other hospital.

Meatal stenosis generally occurs in 0-7% of patients after hypospadias repair as seen in different case series<sup>12,13</sup>. In our case series meatal stenosis was seen in 2 patients (5%). Complications usually occur in the first year after the second stage and are higher in secondary repairs. Complications tend to decrease as the experience increase and use of additional water proofing layer contributes to reduce the fistula rate significantly.<sup>12,13</sup>

Undisputed value of two stage repair lie in those cases where it is necessary to transect and excise the urethral plate there by creating a full circumference defect<sup>14,15,16</sup>.

Inner prepuce is an ideal urethral substitute. It is very thin and flexible and takes reliably. Oral mucosa buccal, labial or lingual is widely used as an alternative to inner prepuce<sup>17</sup>. Two stage repair in our case series is confined to those cases where it is impractical to maintain the axial integrity of urethral plate.

## CONCLUSION

Tubularized incised plate urethroplasty offers excellent cosmetic and functional results for distal hypospadias repair. Bracka two-stage repair is a safe and reliable approach in patients with in whom the urethral plate cannot be incorporated in the repair and requires substitution. These include primary hypospadias with severe curvature, most of proximal hypospadias and complex redo cases.

---

## REFERENCES

1. W. Snodgrass. Hypospadias reporting-how good is the literature? J Urol.2010; 184:1255-1256.
2. I Eardley, R H Whitaker. Surgery for Hypospadias fistula. Br J Urol. 1992, 69; 306-10.
3. Smith ED History of hypospadias surgery. Pediatric Surg Int. 1997; 12: 81-5.
4. Donnahoo KK, Cain M, et al. Etiology, management and surgical complications of congenital chordee without hypospadias. J Urol 1998; 160: 1120-2.
5. Snodgrass W. Tubularized incised plate urethroplasty for distal hypospadias J.Urol.151: 464-5.1994.
6. W. Snodgrass, A. Macedo, P. Hoebeke. Hypospadias dilemmas: a round table. J Pediatric Urol. 2011; 7:145.
7. Bhat A, Mandal AK. Acute postoperative complications of hypospadias repair. Indian J Urol 2008; 24:241-8.
8. Bracka A. A versatile two-stage repair. Br J Plast Surg 1995; 48: 345-52.
9. Steckler, R. E. Zaontz . Stent-freen Thiersch-Duplay hypospadias repair with the Snodgrass modification. J Urol 1997;158: 1178-1180.
10. Bleustein CB, Esposito MP, Felsen D, Mechanism of healing following the Snodgrass repair. J Urol 2001; 165: 277.279.
11. Retik AB, Atala A. Complications of hypospadias repair. Urol Clin North Am 2002; 29: 329-339.
12. W. Snodgrass, A. Macedo, P. Hoebeke, Hypospadias dilemmas: a round table. J Pediatr Urol. 2011;7:145
13. Aslam M, Obaidullah, Mumtaz N. Outcome of urethrocutaneous Fistula repair after hypospadias. Pakistan J Med Res 2005; 44: 23-6.
14. Gill NA, Hameed A: Management of hypospadias cripples with two-staged Bracka's technique. J Plast Reconstr Aesthet Surg. 2011; 64: 91-6.
15. Leslie B, Lorenzo AJ, et al: Critical outcome analysis of staged buccal mucosa graft urethroplasty for prior failed hypospadias repair in children. J Urol. 2011; 185: 1077-82.
16. M. Castagnetti, A. El-Ghoneimi. Surgical management of primary severe hypospadias in children: 20-year review. J Urol. 2010; 184:1469-1474.
17. Onol SY, Onol FF, Erdem MR. Reconstruction of distal urethral strictures confined to the glans with circular buccal mucosa graft. Urology 2012; 79:1158-62.

## AUTHORS

- **Dr. Yawar Sajjad**  
Assistant Professor  
Plastic & Reconstructive Surgery  
Punjab Post Graduate Medical Institute,  
Lahore General Hospital, Lahore
- **Dr. Afsar Ali**  
Associate Professor of Surgery  
Punjab Post Graduate Medical Institute,  
Lahore General Hospital, Lahore
- **Dr. Tanveer Anwar**  
Assistant Professor of Surgery  
Punjab Post Graduate Medical Institute,  
Lahore General Hospital, Lahore

Submitted for Publication: 16-12-2013

Accepted for Publication: 22-01-2014

After minor revisions